

## *Undifferentiated carcinoma of the sinonasal cavity: A diligent diagnosis*

D. Myoteri <sup>1</sup>, D. Dellaportas <sup>2</sup>, A. Tsavari <sup>1</sup>, L. Tsagkaroulaki <sup>3</sup>, H. Moschouris <sup>4</sup>, A. Kamperos <sup>3</sup>, A. Zizi-Sermpetzoglou <sup>1</sup>

<sup>1</sup> Department of Pathology, General Hospital «Tzaneio», Piraeus, Greece, <sup>2</sup> Second Department of Surgery, Aretaieion University Hospital, Athens, Greece, <sup>3</sup> ENT Department, General Hospital «Tzaneio», Piraeus, Greece, <sup>4</sup> Department of Radiology, General Hospital «Tzaneio», Piraeus, Greece

### ABSTRACT

**Introduction:** Sinonasal undifferentiated carcinoma is a scarce, highly aggressive however clinicopathologically distinctive tumor, which usually affects the superior nasal cavity or the paranasal sinuses.

**Case presentation:** A 54-year-old man with left nasal obstruction and intermittent epistaxis was found on anterior rhinoscopy confirmed by nasal endoscopic examination with a reddish/grey friable tumor occupying the lower two thirds of the aforementioned nasal cavity. Imaging modalities showed localized disease and he underwent a successful intranasal resection of the tumor. Histopathology with the aid of immunohistochemistry finally set the diagnosis of sinonasal undifferentiated carcinoma.

**Discussion:** The lesion's aetiology remains unknown. Nasal obstruction, epistaxis, proptosis, visual disturbances, facial pain as well as symptoms of cranial nerve involvement are the usually reported patient's complains. Early symptoms are vague and non-specific, leading to delay in seeking and obtaining treatment. Histopathological diagnosis poses a challenge and differential diagnosis is wide, and despite multimodality treatment approach, prognosis remains dismal.

**Keywords:** sinonasal; undifferentiated carcinoma; malignancy; epistaxis



Citation

D. Myoteri, D. Dellaportas, A. Tsavari, L. Tsagkaroulaki, H. Moschouris, A. Kamperos, A. Zizi-Sermpetzoglou. Undifferentiated carcinoma of the sinonasal cavity: A diligent diagnosis. *Scientific Chronicles* 2016; 21(1): 97-103

*Corresponding Author*

Despoina Myoteri, E-mail addresses: [dmyoteri@gmail.com](mailto:dmyoteri@gmail.com)

## INTRODUCTION

It is well known that the sinonasal tract gives rise to a number of different histopathological types of neoplasms. Sinonasal undifferentiated carcinoma (SNUC) is a scarce, highly aggressive however clinicopathologically distinctive tumour, which usually affects the superior nasal cavity or the paranasal sinuses [1, 2].

Although there is uncertainty about the histogenesis of this tumour, the prevailing theory is that this neoplasm is best described as a large cell neuroendocrine carcinoma [3]. The distinction of SNUC from other sinonasal neoplasms is of paramount importance because of its aggressive behaviour, poor prognosis with commonly a dismal outcome. Immunohistochemistry is of high value and has improved our diagnostic accuracy, which is most likely the reason for the recent increase in the incidence of SNUCs reported in the literature [4].

The aim of this study is to present a case of SNUC treated to our hospital and to briefly discuss the current concepts of histopathological diagnosis of this rare entity.

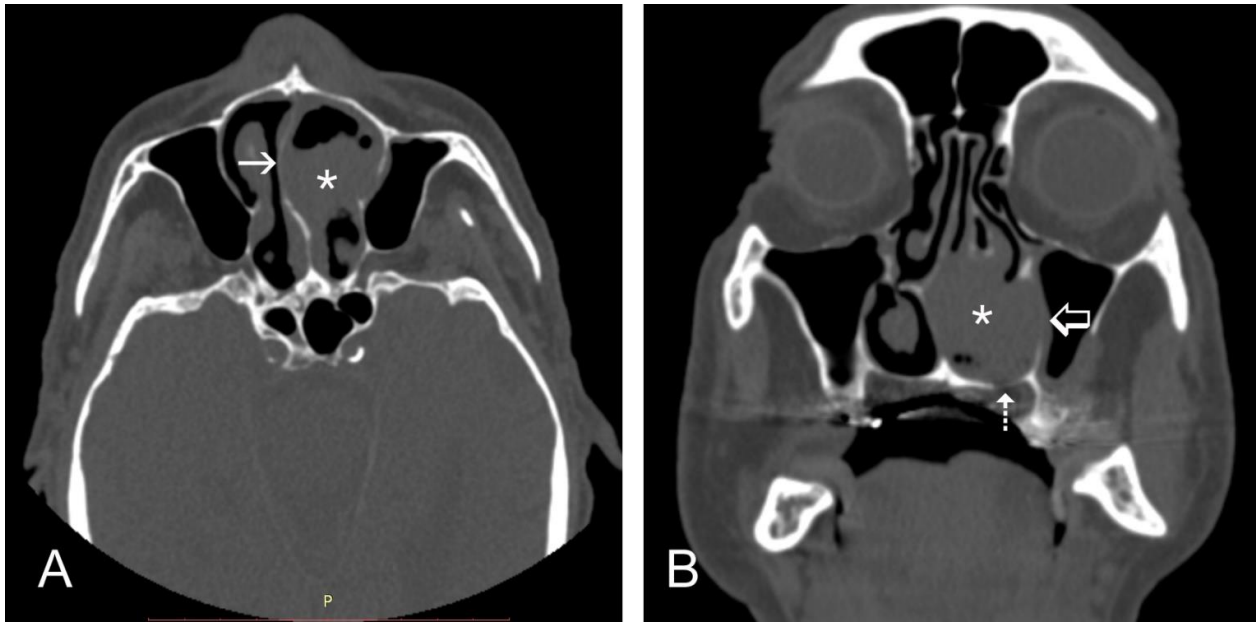
## CASE PRESENTATION

A 54-year-old white male patient presented to the ENT outpatient clinic of our hospital for evaluation of left nasal obstruction sensation noticed initially about a year ago. He also complained of intermittent nasal bleeding for the last 4 months. He was working as a taxi driver, also was a heavy smoker of 70pack/years and drank 42 units

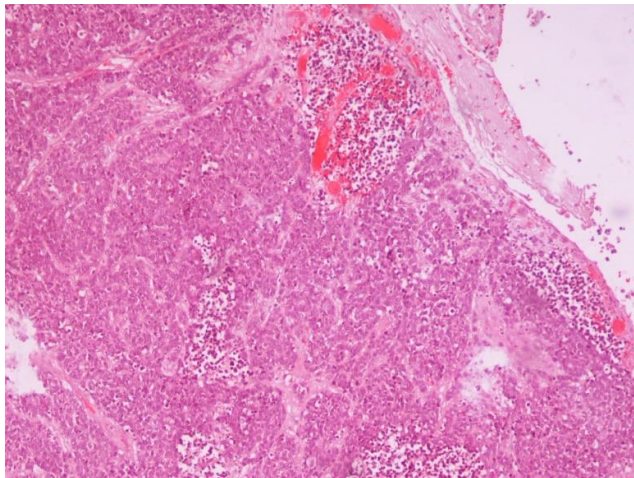
of alcohol per week. His past medical and surgical history were insignificant.

On anterior rhinoscopy, a grey/white mass covered with slough was revealed, encompassing most of the left nasal cavity. Nasal endoscopic examination followed and showed a reddish/grey friable tumour occupying the lower two thirds of the aforementioned nasal cavity. Mass was bleeding easily on light touch and was also painful. On the contrary, nasopharynx was found bilaterally normal. Moreover, ophthalmologic tests and physical examination were normal and metastatic workup was negative. Computed tomography (CT) of the head and sinuses revealed an expansile lesion, occupying the lower two thirds of the left nasal cavity, causing contralateral deviation and thinning of the nasal septum as well as of the floor of the left nasal cavity, with no evidence of intracranial involvement (Figure 1). Surgical excision was decided and the patient underwent an uneventful endoscopic intranasal resection of the tumour.

Histopathological examination revealed a poorly differentiated tumour composed of medium to large, round to ovoid cells arranged in sheets and cords, associated with foci of necrosis and random comedo-like pattern (Figure 2). Moreover there was prominent nuclear pleomorphism, with areas where the nuclear morphology was indistinct with an irregular outline. A great number of atypical mitoses were observed (Figure 3). There was no evidence of squamous or glandular differentiation and no Homer-Wright rosettes or a fibrillary matrix was evident. Dense lymphoid infiltrates were absent.



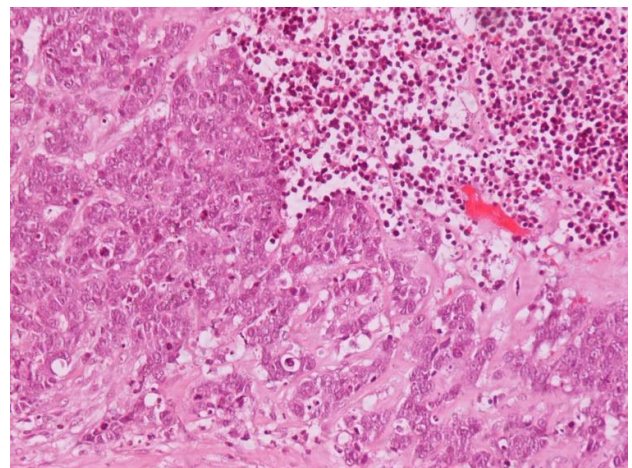
**Figure 1:** CT imaging of the tumor. Axial (A) and coronal (B) CT images (bone algorithm) show a soft tissue mass (asterisks), occupying the two lower thirds of the left nasal cavity. The lesion causes deviation and thinning of the nasal septum (arrow) and thinning of the floor of the left nasal cavity (dotted arrow). There is incipient extension into the left maxillary antrum (open arrow)



**Figure 2:** Solid nests of neoplastic cells, intermingled with aggregates of neutrophils (H-E x 40)

Immunohistochemistry revealed strong positivity for the epithelial markers AE1/AE3, Cam 5.2, CK7 (Figure 4) and CK19 as well as expression of EMA. From the neuroendocrine markers: NSE was positive

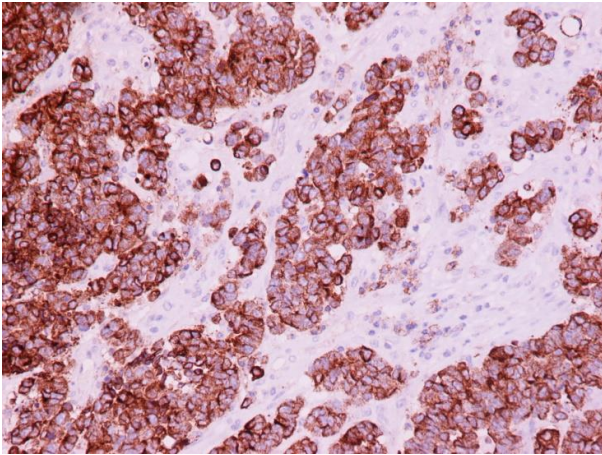
but synaptophysin and chromogranin A were negative. Negative was also the immunohistochemical detection of Epstein-Barr virus (EBV).



**Figure 3:** Medium to large-sized neoplastic cells with prominent nucleoli. Note the presence of brisk mitotic activity (H-Ex200)

Based on the above histopathologic and immunohistochemical findings, the diagnosis





**Figure 4:** Neoplastic cells stain positive for CK7 (CK7x200)

of SNUC was confidently set. The patient after multidisciplinary team discussion received adjuvant chemoradiation therapy. In his follow-up visit six months later he remains disease free.

## DISCUSSION

Sinonasal undifferentiated carcinoma (SNUC) is a unique clinicopathologic entity of the sinonasal tract, first described by Freirson et al in 1986 [5]. Before this time, aggressive neoplasms of this site were characterized as anaplastic or undifferentiated carcinomas without a distinctive diagnosis. SNUC usually involves the superior nasal cavity and paranasal sinuses [6]. In addition, it frequently involves multiple sites, often with evidence of extension beyond the anatomic boundaries of the sinonasal tract. Men are more commonly affected with a male to female ratio of 2.3:1 and although the age range is broad, the median age at diagnosis mostly affects the sixth decade of life [7].

The aetiology of SNUC remains practically unknown. There is a connection in personal history of some cases with radiation therapy for retinoblastoma or nasopharyngeal carcinoma [8]. Smoking is also probably a risk factor. EBV and its role in the development of SNUC have been ambiguous for decades but it is now widely accepted that the involvement of EBV in the pathogenesis of SNUC is unlikely. In practice, the presence of EBV excludes a diagnosis of SNUC [9].

Symptoms of SNUC usually have a rapid onset and short duration, which coincides with the tumour's large size and aggressive invasion of adjacent structures. Nasal obstruction, epistaxis, proptosis, visual disturbances, facial pain as well as symptoms of cranial nerve involvement are the usually reported patient's complains. As happens with most futile malignancies, early symptoms of SNUC are vague and non-specific, leading to delay in seeking and obtaining treatment.

SNUC entails a challenging histopathological diagnosis mostly because of the lesion's propensity to be composed of relatively small, round to round-spindled identical undifferentiated cells. Thus, the differential diagnosis of such an undifferentiated small blue cell malignancy is wide and contains representatives from almost all major categories of neoplasms: carcinomas, sarcomas, lymphomas and neuroendocrine-neuroectodermal tumours are included in the long list. More specifically, the differential diagnosis of SNUC includes large cell lymphoma, undifferentiated (lymphoepithelioma-like) carcinoma, small cell (neuroendocrine)

undifferentiated carcinoma (SCUC), olfactory neuroblastoma (ONB) [10]. Immunohistochemical staining has the ability to distinguish between SNUC and large cell lymphoma. Moreover, the conspicuous lymphoplasmacytic infiltrate of other undifferentiated carcinomas is not a typical feature of SNUC. Also, the malignant cells of SNUC have distinct cytoplasmic borders, in comparison with the undifferentiated carcinoma cells, which demonstrate syncytial growth. Additionally, the tumour cells of SNUC are distinctly larger of SCUC cells, with more prominent eosinophilic cytoplasm and large nuclei. Generally, whenever SCUC is considered in this anatomic region, it is important to remember that true cases of SCUC are extremely rare in the sinonasal tract.

Seldom arising sinonasal tumours are challenging clinical entities for head and neck multidisciplinary teams. SNUC presents usually as locally advanced disease maintaining extremely difficult to treat. Briefly, most studies agree that surgery is the mainstay of treatment for resectable tumours, with the addition of chemotherapy and radiotherapy as adjuvant modalities, providing additional survival benefits [11]. Surgical resection typically entails extensive

craniofacial resections, encompassing maxillectomy, orbital exenteration, and neurosurgical consultation for complex cases. Chemotherapy agents commonly used include carboplatin, cisplatin, and etoposide. However, even with this multi-modality approach, the disease control for SNUC is disappointing. High recurrence rates, early metastatic disease and survival counted in months after the diagnosis is the norm for SNUC patients.

Alternative approaches that have been attempted include boron neutron capture therapy, autologous bone marrow transplant, and neoadjuvant selective intra-arterial cisplatin with concurrent radiation therapy, unfortunately with limited success [12-14]. A recent study of a small series of SNUC patients showed that these tumours have a strong expression c-KIT [15], the well-known from gastrointestinal stromal tumours tyrosine kinase receptor, and targeted therapies might develop in the future for this lethal malignancy.

In conclusion, SNUC is a futile malignancy and histopathological diagnosis remains a challenge, with immunohistochemistry being the major contributor to the right diagnostic direction.

#### **Author's statement**

The authors declare that there is no conflict of interests regarding the publication of this paper.

#### **REFERENCES**

1. Wenig BM. Undifferentiated malignant neoplasms of the sinonasal tract. Arch Pathol Lab Med 2009; 133: 699-712.

2. Van Crombrugge L, De Vos G, Vanclooster C et al. The simultaneous appearance of a nasal natural killer-cell lymphoma and acute myelogenous leukemia. *B-ENT* 2012; 8: 49-52.
3. Ejaz A, Wenig BM. Sinonasal undifferentiated carcinoma: clinical and pathologic features and a discussion on classification, cellular differentiation, and differential diagnosis. *Adv Anat Pathol* 2005; 12: 134-143.
4. Bellizzi AM, Bourne TD, Mills SE, Stelow EB. The cytologic features of sinonasal undifferentiated carcinoma and olfactory neuroblastoma. *Am J Clin Pathol* 2008; 129: 367-376.
5. Frierson HF, Jr., Mills SE, Fechner RE et al. Sinonasal undifferentiated carcinoma. An aggressive neoplasm derived from schneiderian epithelium and distinct from olfactory neuroblastoma. *Am J Surg Pathol* 1986; 10: 771-779.
6. Xu CC, Dziegielewski PT, McGaw WT, Seikaly H. Sinonasal undifferentiated carcinoma (SNUC): the Alberta experience and literature review. *J Otolaryngol Head Neck Surg* 2013; 42: 2.
7. Reiersen DA, Pahilan ME, Devaiah AK. Meta-analysis of treatment outcomes for sinonasal undifferentiated carcinoma. *Otolaryngol Head Neck Surg* 2012; 147: 7-14.
8. Klein EA, Anzil AP, Mezzacappa P et al. Sinonasal primitive neuroectodermal tumor arising in a long-term survivor of heritable unilateral retinoblastoma. *Cancer* 1992; 70: 423-431.
9. Shinokuma A, Hirakawa N, Tamiya S et al. Evaluation of Epstein-Barr virus infection in sinonasal small round cell tumors. *J Cancer Res Clin Oncol* 2000; 126: 12-18.
10. Bell D, Hanna EY. Sinonasal undifferentiated carcinoma: morphological heterogeneity, diagnosis, management and biological markers. *Expert Rev Anticancer Ther* 2013; 13: 285-296.
11. Mourad WF, Hauerstock D, Shourbaji RA et al. Trimodality management of sinonasal undifferentiated carcinoma and review of the literature. *Am J Clin Oncol* 2013; 36: 584-588.
12. Ansari M, Guo S, Fakhri S et al. Sinonasal undifferentiated carcinoma (SNUC): morphoproteomic-guided treatment paradigm with clinical efficacy. *Ann Clin Lab Sci* 2013; 43: 45-53.
13. Stewart FM, Lazarus HM, Levine PA et al. High-dose chemotherapy and autologous marrow transplantation for esthesioneuroblastoma and sinonasal undifferentiated carcinoma. *Am J Clin Oncol* 1989; 12: 217-221.
14. Noticewala SS, Mell LK, Olson SE, Read W. Survival in unresectable sinonasal undifferentiated carcinoma treated with concurrent intra-arterial cisplatin and radiation. *World J Clin Cases* 2015; 3: 191-195.
15. Chernock RD, Perry A, Pfeifer JD et al. Receptor tyrosine kinases in sinonasal undifferentiated carcinomas--evaluation for EGFR, c-KIT, and HER2/neu expression. *Head Neck* 2009; 31: 919-927.

## Αδιαφοροποίητο καρκίνωμα της ρινοφαρυγγικής κοιλότητας: Μια φιλόπονη διάγνωση

Δ. Μυωτέρη <sup>1</sup>, Δ. Δελλαπόρτας <sup>2</sup>, Α. Τσαβαρή <sup>1</sup>, Λ. Τσαγκαρουλάκη <sup>3</sup>, Ι. Μοσχούρης <sup>4</sup>, Α. Καμπέρος <sup>3</sup>, Α. Ζήζη-Σερμπετζόγλου <sup>1</sup>

<sup>1</sup> Παθολογοανατομικό Εργαστήριο, Γενικό Νοσοκομείο Πειραιά «Τζάνειο», <sup>2</sup> Β' Χειρουργική Κλινική Πανεπιστημίου Αθηνών «Αρεταίειο Νοσοκομείο», <sup>3</sup> Ωτορινολαρυγγική Κλινική και <sup>4</sup> Ακτινολογικό Εργαστήριο, Γενικό Νοσοκομείο Πειραιά «Τζάνειο»

### ΠΕΡΙΛΗΨΗ

Εισαγωγή: Το αδιαφοροποίητο ρινοφαρυγγικό καρκίνωμα είναι μια εξαιρετικά σπάνια κλινική οντότητα, με επιθετική κλινική συμπεριφορά καταλαμβάνοντας την ανώτερη συνήθως ρινική κοιλότητα ή τους παραρινίους κόλπους. Παρ' όλα αυτά η παθολογοανατομική του εικόνα είναι χαρακτηριστική.

Παρουσίαση περιστατικού: Ένας άνδρας 54 ετών με αποφρακτικά συμπτώματα της αριστερής ρινός και επεισόδια επίσταξης υπεβλήθη σε πρόσθια ρινοσκόπηση και ακολούθως σε ρινοενδοσκόπηση, όπου ανεδείχθη ένας κοκκινωπός/γκρι εθθρυπτος όγκος να καταλαμβάνει τα κατώτερα δύο τρίτα της εν λόγω ρινικής κοιλότητας. Οι απεικονιστικές εξετάσεις επιβεβαίωσαν τη νόσο, που ήταν περιορισμένη χωρίς απομακρυσμένες μεταστάσεις οπότε και απεφασίσθη η χειρουργική εκτομή. Διενεργήθη μια επιτυχημένη ενδορινική εκτομή του όγκου. Η παθολογοανατομική εξέταση κατέληξε μετά από ενδελεχή μελέτη στη διάγνωση του αδιαφοροποίητου ρινοφαρυγγικού καρκινώματος.

Συζήτηση: Η αιτιολογία της βλάβης παραμένει ασαφής. Η αίσθηση πληρότητας, η απόφραξη, η επίσταξη, οπτικές διαταραχές, πόνος στο πρόσωπο και συμπτώματα σχετιζόμενα με προσβολή των κρανιακών νεύρων είναι η συνήθης συμπτωματολογία του όγκου. Δυστυχώς τα πρώιμα συμπτώματα είναι αμβληγρά και μη ειδικά, οδηγώντας σε σημαντική καθυστέρηση στη διάγνωση και τελικά στη θεραπεία. Η ορθή παθολογοανατομική διάγνωση είναι μια πρόκληση και η διαφορική διάγνωση ευρεία, και παρά την πολυπαραγοντική θεραπευτική προσέγγιση, η πρόγνωση παραμένει εξαιρετικά πτωχή.



**Λέξεις Ευρητηρίου:** στενώματα ουρήθρας, ουρηθροτομή, αγγειογραφικές τεχνικές.



Παραπομπή

Δ. Μυωτέρη, Δ. Δελλαπόρτας, Α. Τσαβαρή, Λ. Τσαγκαρουλάκη, Ι. Μοσχούρης, Α. Καμπέρος, Α. Ζήζη-Σερμπετζόγλου. Αδιαφοροποίητο καρκίνωμα της ρινοφαρυγγικής κοιλότητας: Μια φιλόπονη διάγνωση. *Επιστημονικά Χρονικά* 2016;21(1): 97-103