

## Splenogonadal fusion. A case report

K. Stamatiou <sup>1</sup>, A. Marinis <sup>2</sup>, H. Moschouris <sup>3</sup>, K. Manoloudaki <sup>4</sup>, K. Koulia <sup>4</sup>, A. Tsavari <sup>4</sup>, T. Vasilakaki <sup>4</sup>

<sup>1</sup>Urology Department, <sup>2</sup>First Department of Surgery, <sup>3</sup>Radiology Department, <sup>4</sup>Pathology Department, General Hospital «Tzaneio», Piraeus, Greece

### ABSTRACT

Splenogonadal fusion is a rare anomaly consisted of abnormal connection between spleen and gonad or derivatives of the mesonephros. It is usually presented as a painless scrotal mass in children, adolescents or men younger than 25 yoa. In most of the cases the diagnosis is made at pathologic examination of the removed tissue. The scarceness of reports in the literature underlines the rarity of this entity. Here we report a case of splenogonadal fusion in a 19-year-old male with a torsed testicle and history of polytrauma.



**Keywords:** Hydrocoele; spleen; splenogonadal fusion, testicle; torsion



### Citation

K. Stamatiou, A. Marinis, H. Moschouris, K. Manoloudaki, K. Koulia, A. Tsavari, T. Vasilakaki. Splenogonadal fusion. A case report. *Scientific Chronicles* 2016; 21(1): 104-110

*Corresponding Author*

Konstantinos Stamatiou, E-mail addresses: [stamatiouk@gmail.com](mailto:stamatiouk@gmail.com)

## INTRODUCTION

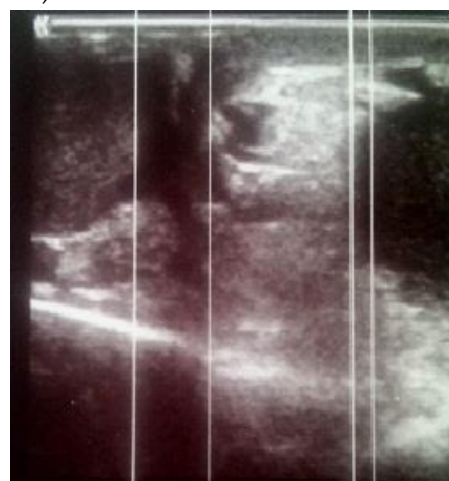Splenogonadal fusion (SGF) is a rare benign congenital anomaly consisted of abnormal connection between spleen and gonad or derivatives of the mesonephros [1]. Since the immature splenic tissue is pulled in a caudal direction with descent of the gonad, the abnormality is expected to be located on the left side where it adheres to the developing testicle, epididymis or vas deferens [2]. In fact, in almost all reported cases the SGF was located in the left side while only a single case was occurred on the right side [3]. The incidence of SGF is practically unknown and it is believed that the real incidence is probably underestimated [4]. Although the aetiology of this entity still remains uncertain, it is believed that it is secondary to injury of the foetus during intrauterine life. However, based on a disparity in male to female ratio of its incidence (approximately 16:1) some researchers suggested a rare genetic predisposition [5]. In confirmation to the above, a worth mentioning percentage of SGF's (almost one-third of the cases) have been linked with other congenital abnormalities including limb and orofacial malformations, Moebius syndrome and intestinal intussusception [5]. Here we report a case of splenogonadal fusion in a 19-year-old male with a torsed testicle and history of polytrauma.

## CASE PRESENTATION

A 19 year old male patient, with history of polytrauma and long term hospitalisation in intensive care unit was admitted to the outpatient department complaining of gradual enlargement of an asymptomatic swelling on the left side of his

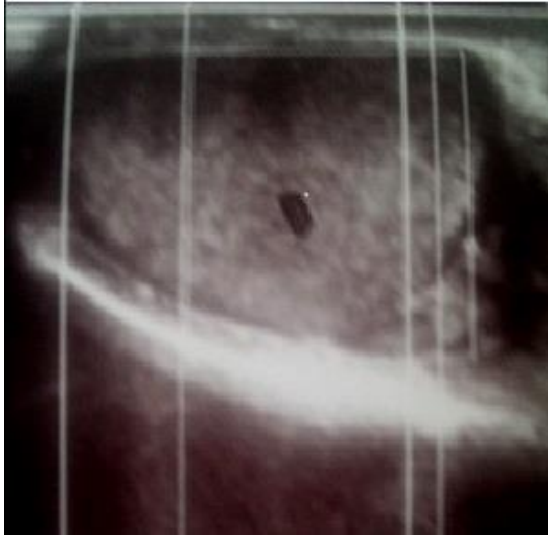scrotal sac. He also reported worsening pain of the left semi scrotum lasting for 3 days one month prior to his admission. His medical history included splenic rupture, renal blunt trauma, multiple bone fractures and pneumothorax due to traffic accident. A year after he was discharged he developed left hernia. Occasionally he suffered of mild pain in the left inguinal region and he rarely felt severe scrotal pain.

On palpation, a left hernia was noted. The affected semi-scrotum was enlarged and contained a large hydrocoele. The epididymis was normal while the testis was painless, slightly enlarged and hard in palpation. Laboratory examination revealed no pathologic findings except mild leukocytosis. Specific tumor markers such as b- human chorionic gonadotropin ( $\beta$ -hCG) and Alpha-fetoprotein (AFP) were within normal ranges. Ultrasound of the scrotum showed two oviform hypo-enhanced lesions of approximately 1,5 cm in diameter located in the middle line and the lower pole of the left testicle. The centrally located lesion was also characterized by an anechoic central area (figure 1).



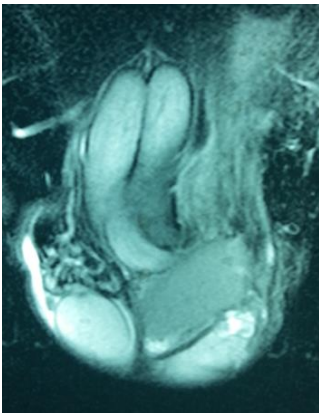
**Figure 1.** A mass above the upper pole of the testicle with smooth outline, regular echogenicity with no calcifications.

There was also a mass above the upper pole of the testicle about 8 X6 mm with smooth outline, regular echogenicity with no calcifications described as hydrocele of the ipsilateral semi-scrotum (figure 2).



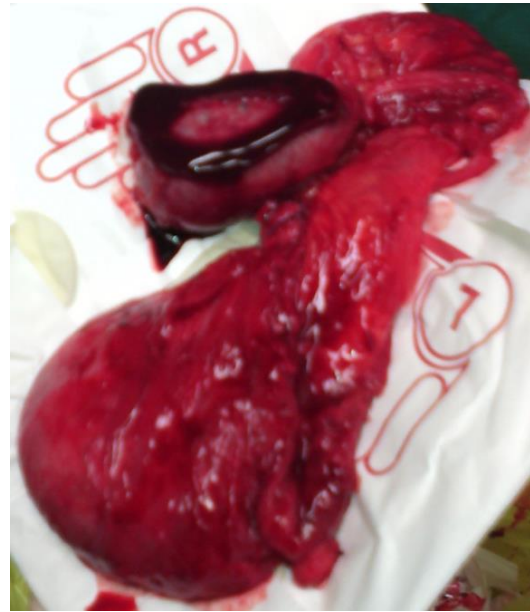
**Figure 2.** Ultrasound of the scrotum showing ovoid hypo-enhanced lesions of the left testicle. The centrally located lesion was also characterized by an anechoic central area.

There was prominent flow involving mainly hydrocele noted with power Doppler. The MRI scan showed no abnormality of the left testicle which was displaced by the hernia (figure 3).



**Figure 3.** Coronal T2 weighted image of the scrotum demonstrates an ovoid, well-defined lesion, of intermediate signal intensity above and medial to the left testis.

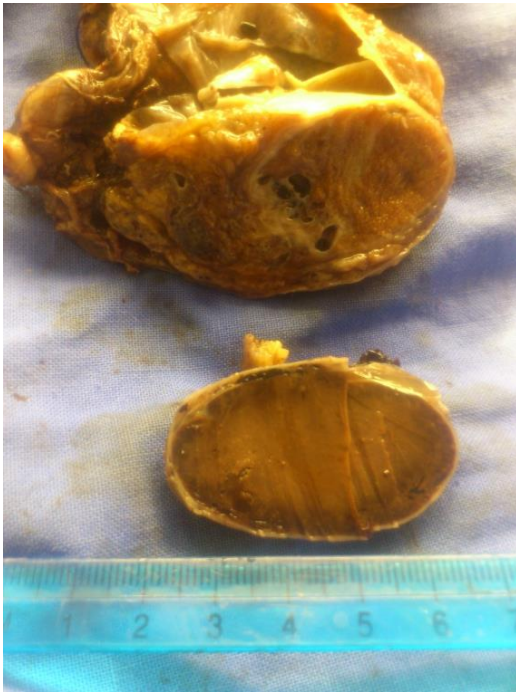A standard left inguinal incision was used at surgery and exploration revealed a dark coloured left testicle which had normal shape and was hard in palpation. A thick sack containing epididymis, vas deferens and blood vessels as well as a fine, dark-red, tubular structure was also seen (figure 4).



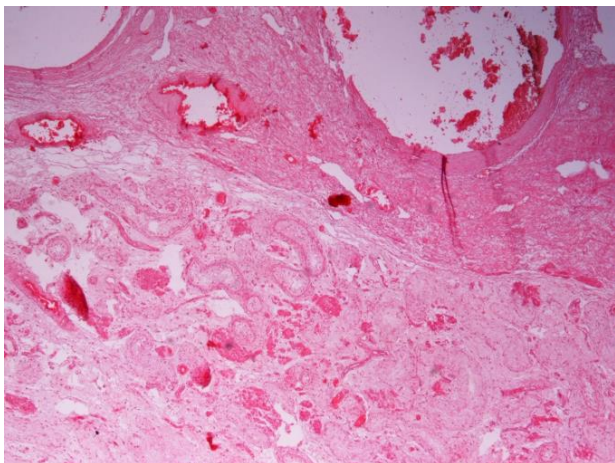
**Figure 4.** A dark coloured left testicle and a thick sack containing epididymis, vas deferens blood vessels and a fine, dark-red, tubular structure as well.

Both the testicle and the above mentioned structure were removed while the underlying hernia was repaired with mesh. Cut section of specimen revealed a torsed testis and paratesticular tissue and a circumscribed lesion composed of mature splenic tissue (figure 5). Histology revealed an atrophic testicular parenchyma adjacent to cystic epididymis. It also revealed the tubular structure to consist of splenic tissue with a fibrous capsule. There was no atypia but simply reactive fibrosis of the tunica vaginalis. These features were consistent with

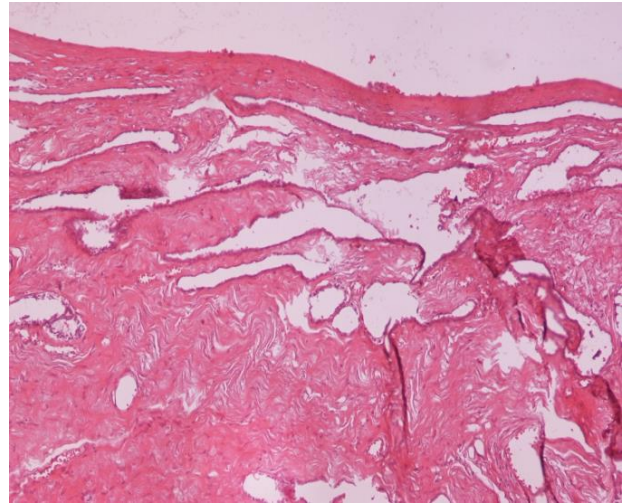
a diagnosis of splenogonadal fusion (figures 6,7).



**Figure 5.** Cut section of specimen revealed a torsed testis and circumscribed lesion composed of mature splenic tissue.



**Figure 6.** Atrophic testicular parenchima adjacent to cystic epididymis (H-Ex4).



**Figure 7.** Splenic tissue adjacent to cystic epididymis (H-Ex2).

## DISCUSSION

Most SFG cases are usually seen before the age of 20 and the 44% are related to cryptorchidism [6]. Therefore, it is possible that SGF may preclude the positioning of the testicle in the scrotum and therefore it could predispose to torsion. A few cases have been diagnosed in advanced age. The above as well as the association of SFG with bilateral cryptorchidism and right intra-abdominal testes may suggest an alternative pathogenic mechanism. For instance, in our case, a migration of fragments of the shuttered spleen to the scrotum through the hernia channel might be the pathogenic mechanism. SFG is rarely diagnosed preoperatively [7]. In fact, there are no specific symptoms characterising this condition and most SFGs' are incidentally diagnosed as asymptomatic masses while exploring inguinal region for some other reasons. They usually presented as a painless soft scrotal mass and/or inguinoscrotal swelling and therefore are misdiagnosed as cryptorchidism, hernia, or hydrocele [2,3]. Given the moderate number

of hernias undergoing surgical repair, it could be assumed that several cases remain undiagnosed.

Rarely SFGs' may cause scrotal pain in association to the involvement of ectopic splenic tissue by malaria, leukemia, infectious mononucleosis, traumatic rupture and mumps [3]. Of acute onset painful scrotal lump originating from the testicle, the most important is secondary to testicular torsion.

Although, testicular neoplasms have been reported in only four cases with splenogonadal fusion, in some instances the testicle-ectopic spleen conjugate is misdiagnosed as testicular cancer leading to unnecessary orchiectomies whose exact number remain unclear [2]. Some authors noted that despite the easy dissection of the splenic tissue from the testicle, unsuspected diagnosis during operative exploration have led to an unnecessary orchiectomy in one third of the reported cases [8, 9].

In addition to malignant tumor, the differential diagnosis of the intra-scrotal paratesticular mass includes also, adrenal rest tissue, epididymitis, orchitis, hemangioma, and hematoma. Ultrasonography is the first imaging study to evaluate this condition. However, the typical vascularized structure connecting the spleen to the splenogonadal mass is not always present and/or visible [10]. The use of the colour Doppler examination may enhance diagnostic accuracy [10]. In our case additionally to the

presence of paratesticular mass, the health status of the adjacent testicle was also undefined. In ultrasound examination the typical imaging of testicular tumors (irregular echotexture and vascularity) was absent; the oviform intratesticular lesions were hypo-enhanced and hypo-vascularised. Of note, in our case, MRI failed to differentiate splenogonadal fusion from a hernia and a normal testicle from a torsioned one.

Several authors suggest intra-operatively, pathological examination of a frozen section of the testicular biopsy material to be performed in order to avoid unnecessary orchiectomy [10]. In our case the condition of the testicle rendered orchiectomy necessary. In any other case, treatment of splenogonadal fusion consists of simply dissecting the splenic tissue from the involved gonad and generally leads to complete cure of the patient [3].

## CONCLUSIONS

Splenogonadal fusion is a rare anomaly usually diagnosed upon pathologic examination of the removed tissue. The scarceness of reports in the literature underlines the rarity of this entity. The case we report here may suggest a migration of fragments of the shuttered spleen to the scrotum through the hernia channel as an alternative pathogenic mechanism.

## REFERENCES

1. Putschar WGJ, Manion WC. Splenic-gonadal fusion. *Am J Pathol* 1956;32:15-35
2. Braga LH, Braga MM, Dias MA. Laparoscopic diagnosis and treatment of splenogonadal fusion associated with intra-abdominal cryptorchidism in a child. *Pediatr Surg Int.* 1999;15(7):465-6.
3. Brash J, Roscher AA. Unusual presentation on the right side of ectopic testicular spleen. *Int Surg.* 1987;72:233e234.
4. Alvarez Maestro M, López-Tello J, Domínguez Franjo P, Ríos González E, Martínez-Piñeiro L. Splenogonadal fusion. Report of a case and review of the literature. *Actas Urol Esp.* 2010;34:293-5
5. Buccoliero AM, Messineo A, Castiglione F, et al. Splenogonadal fusion: exceptional association with Moebius syndrome and intestinal intussusception. *Fetal Pediatr Pathol.* 2011;30(4):220-4.
6. Carragher A.M. One hundred years of splenogonadal fusion. *Urol* 1990;35:471-473.
7. Kocher NJ, Tomaszewski JJ, Parsons RB, et al. Splenogonadal fusion: a rare etiology of solid testicular mass. *Urology.* 2014;83(1):e1-2.
8. Sountoulides P, Neri F, Bellocci R, Schips L, Cindolo L. Splenogonadal fusion mimicking a testis tumor. *J Postgrad Med.* 2014;60(2):202-4.
9. Velarde Ramos L, Sepulveda F, Silva E, Castillo OA. Discontinuous intrabdominal splenogonadal fusion with germ cell tumor. Excision with robotic assistance. Adult case report. *Arch Esp Urol.* 2012;65(8):762-5.
10. Ferrón SA, Arce JD. Discontinuous splenogonadal fusion: new sonographic findings. *Pediatr Radiol.* 2013;43(12):1652-5.

## Σπληνογοναδική σύμφυση. Παρουσίαση περιστατικού

Κ. Σταματίου<sup>1</sup>, Α. Μαρίνης<sup>2</sup>, Ι. Μοσχούρης<sup>3</sup>, Κ. Μανωλουδάκη<sup>4</sup>, Κ. Κούλια<sup>4</sup>, Α. Τσαβαρή<sup>4</sup>, Θ. Βασιλακάκη<sup>4</sup>

<sup>1</sup> Ουρολογική Κλινική, <sup>2</sup> Α' Χειρουργική Κλινική, <sup>3</sup> Ακτινολογικό Τμήμα και <sup>4</sup> Παθολογοανατομικό Εργαστήριο, Γενικό Νοσοκομείο Πειραιά «Τζάνειο»

### ΠΕΡΙΛΗΨΗ

Η σπληνογοναδική σύμφυση είναι σπάνια ανωμαλία που αφορά στην μη φυσιολογική γειτνίαση και σύντηξη μεταξύ σπλήνα και των γονάδων ή υπολλείματα του μεσόνεφρου. Συνήθως εμφανίζεται ως μη επώδυνη μάζα στο όσχεο των παιδιών, εφήβων και νέων άνδρων έως 25 ετών. Στις περισσότερες περιπτώσεις η διάγνωση τίθεται με την ιστολογική εξέταση του αφαιρεθέντος ιστού. Η ελάχιστη αναφορά τους στη διεθνή βιβλιογραφία υποδηλώνει τη σπανιότητα της παθήσεως αυτής. Στην εργασία αυτή παρουσιάζουμε περίπτωση σπληνογοναδικής σύμφυσης σε 19 ετών άνδρα με συστραφέντα όρχι και ιστορικό τραύματος.



**Λέξεις Ευρετηρίου:** Υδροκήλη, σπλήνας, σπληνογοναδική σύμφυση, όρχις, συστροφή.



Παραπομπή

Κ. Σταματίου, Α. Μαρίνης, Ι. Μοσχούρης, Κ. Μανωλουδάκη, Κ. Κούλια, Α. Τσαβαρή, Θ. Βασιλακάκη. Σπληνογοναδική σύμφυση. Παρουσίαση περιστατικού. *Επιστημονικά Χρονικά* 2016;21(1): 104-110